

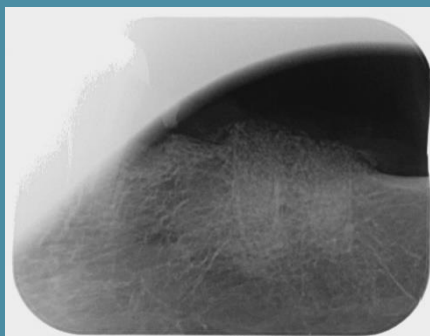
IVORY Graft

Case Report

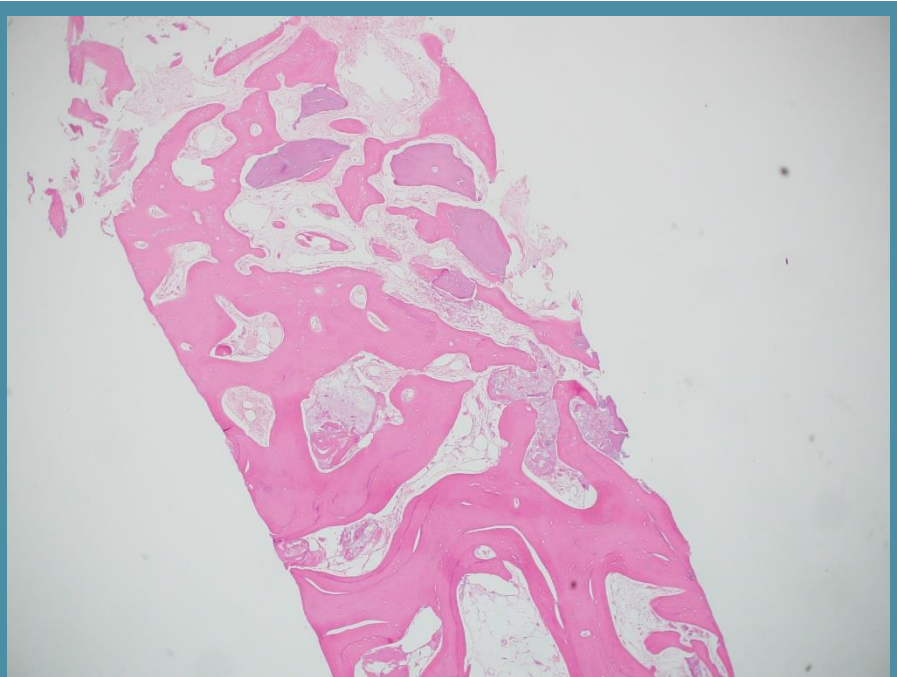
Graft: Ivory's Dentin Bone Graft

Application: Socket preservation

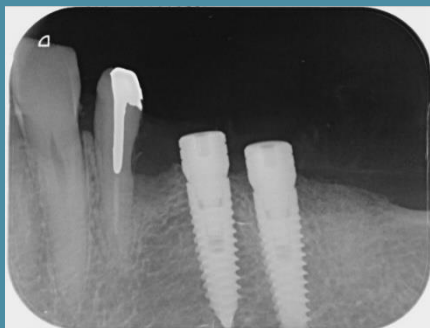By: Doctors at the Clinic for Oral and Maxillofacial Surgery, Shamir Medical Center



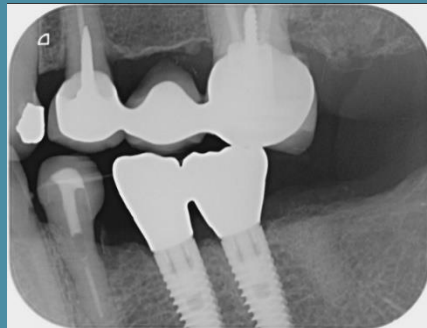
Periapical x-ray scan
After extraction
and bone grafting



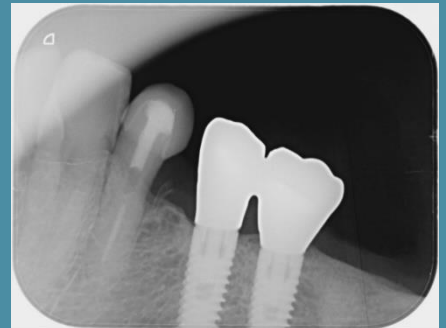
Histology
5 months post grafting



Periapical x-ray scan
5 months post grafting
implant placement



Periapical x-ray scan
4 years post grafting
- with crown (a)



Periapical x-ray scan
4 years post grafting
- with crown (b)