

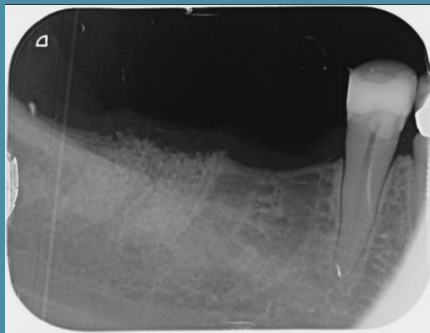
# IVORY Graft

## Case Report

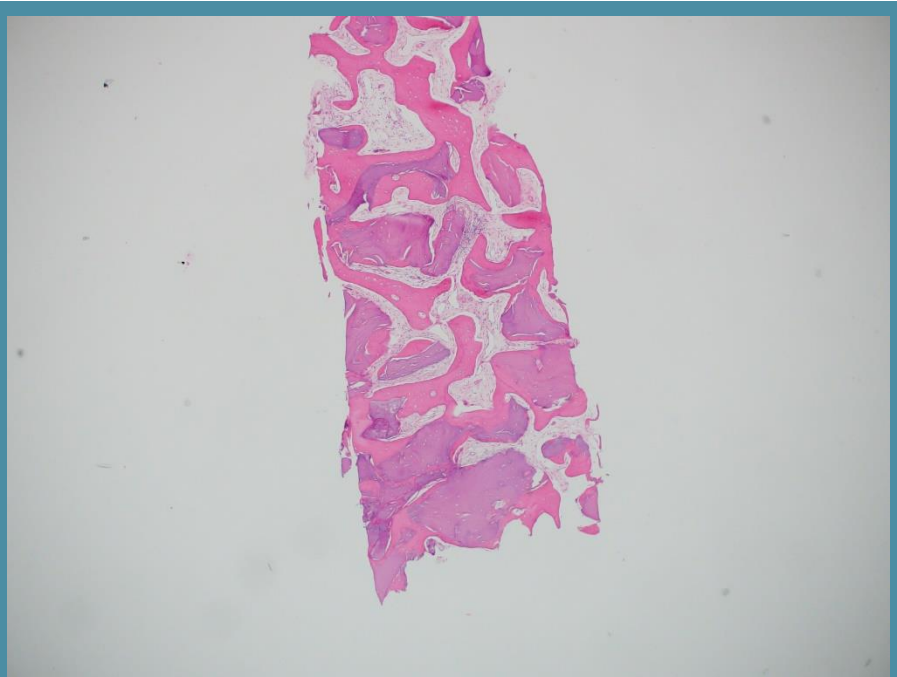
**Graft:** Ivory's Dentin Bone Graft

**Application:** Socket preservation

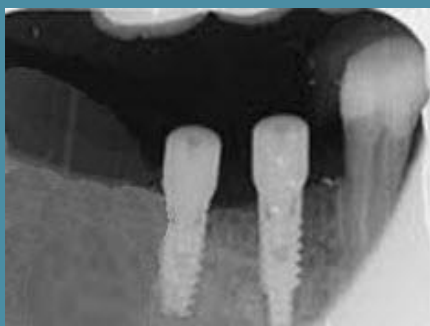**By:** Doctors at the Clinic for Oral and Maxillofacial Surgery, Shamir Medical Center



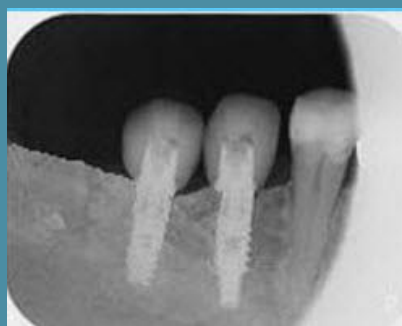**Periapical x-ray scan**  
After extraction



**Histology**  
4 months post grafting



**Periapical x-ray scan**  
4 months post grafting  
- implant placement



**Periapical x-ray scan**  
4 years post grafting  
- with crowns