

IVORY Graft

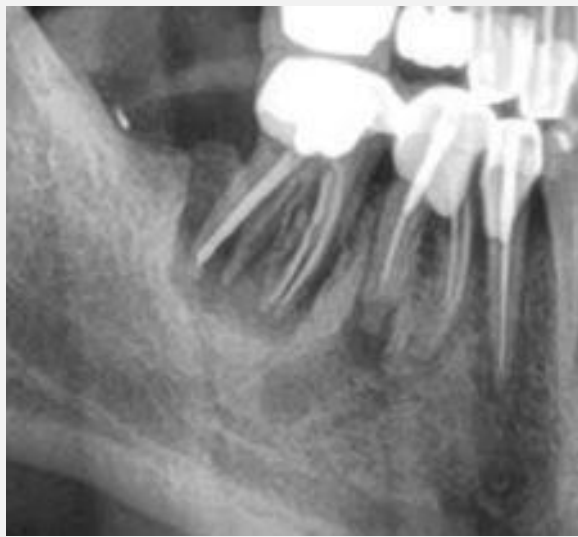Case Report

Patient: Healthy, non-smoking, 58 year old Male

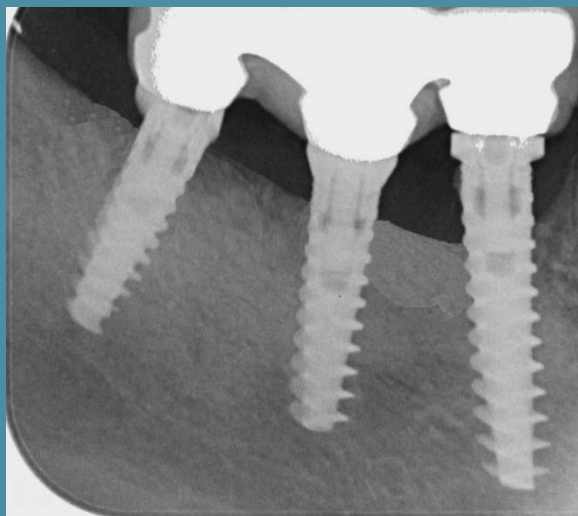
Graft: Ivory's Dentin Bone Graft

Application: Alveolar ridge augmentation

By: Dr. Lari Sapoznikov, DMD, Israel



CBCT scan
Before extraction and bone grafting



Panoramic scan
8 months after bone grafting
5 months after implantation