

IVORY Graft

Case Report

Patient: Healthy non-smoking male, in his early 60's

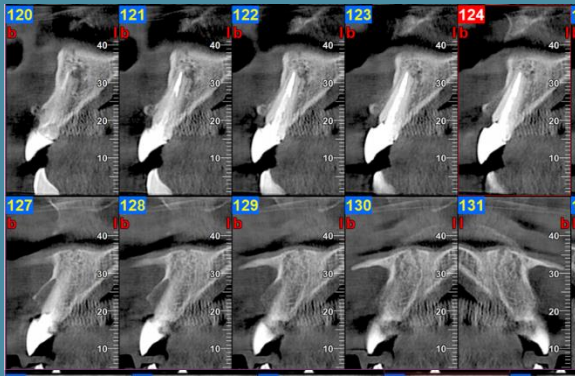
Medical condition: Extraction of tooth 11

Graft: Ivory's Dentin Bone Graft, covered with FGG taken from the tuberosity

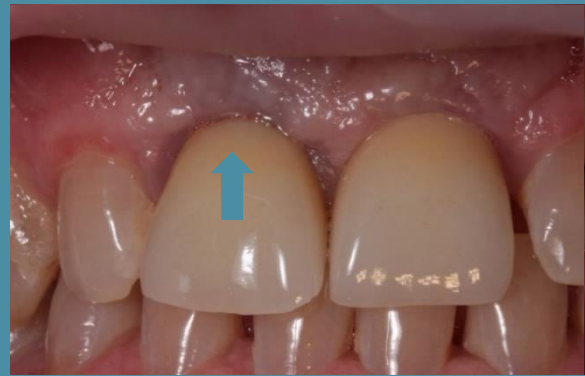Application: Socket preservation

By: Dr. Avi Kuperschlag, D.D.S., Lithuania

Before Extraction and Bone Grafting



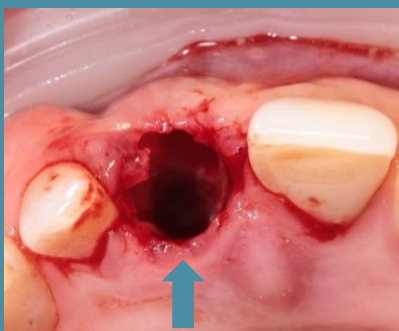
CBCT scan



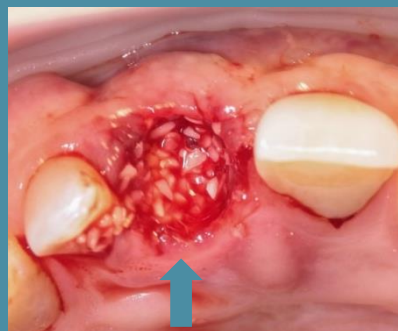Photograph

During Extraction and Bone Grafting

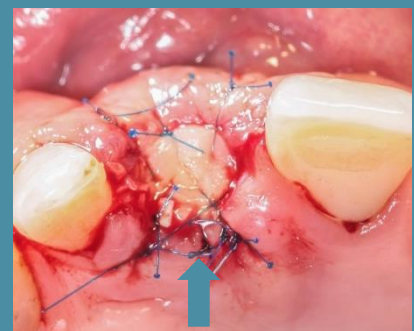
Photographs (below) | [Link to Video](#)



Extraction done

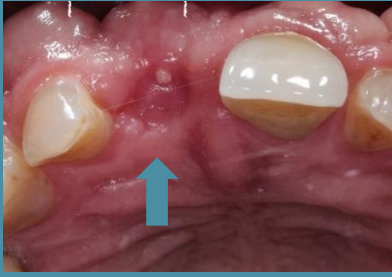

Bone graft added



Suturing completed

6 Weeks After Bone Grafting



Healing

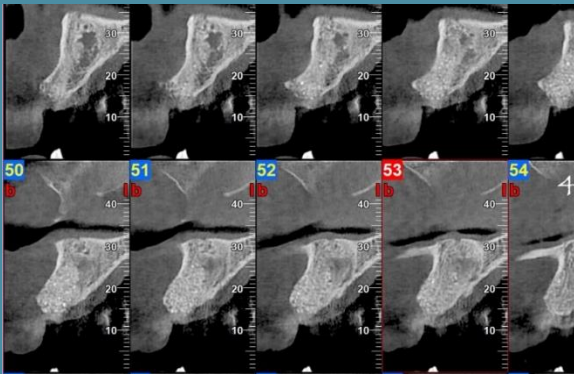
“Note the excellent quality of regenerated bone, allowing great implant fixation and primary stability.”

Dr. Avi Kuperschlag

4 Months After Bone Grafting

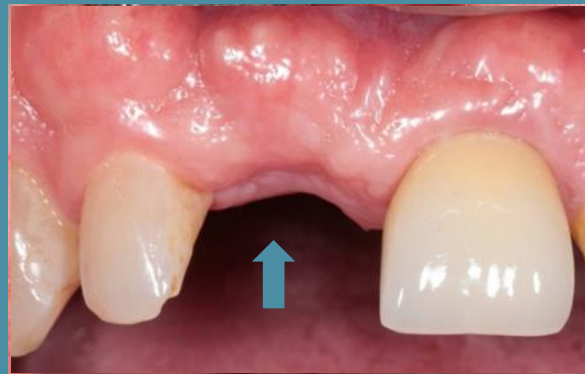Exposure, implant placement and immediate loading

1



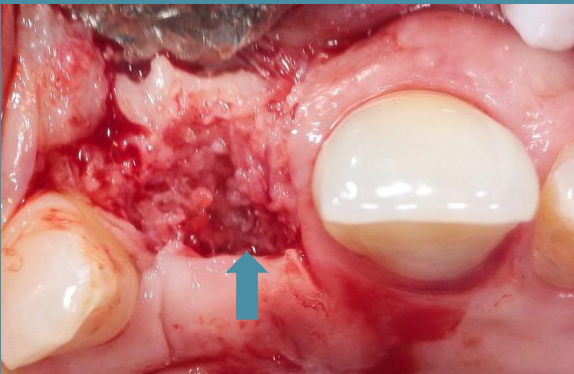
CBCT

2



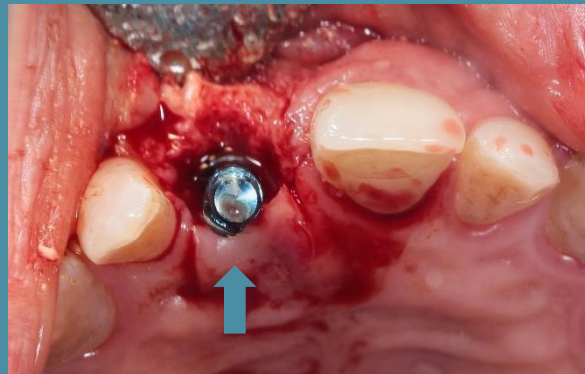
Photograph

3



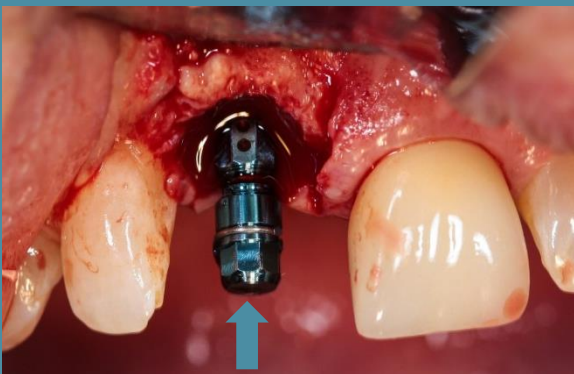
Exposure

4



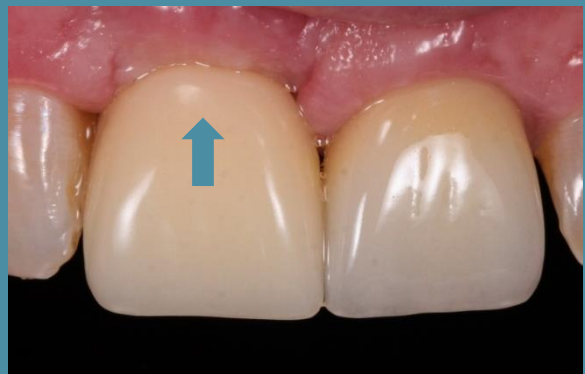Implant Placement

5



Immediate Loading

6



Crown Added