

IVORY Graft

Case Report

Patient: Female patient in her late 50's, regularly taking beta blockers for hypertension

Medical condition: Implantation of tooth 46

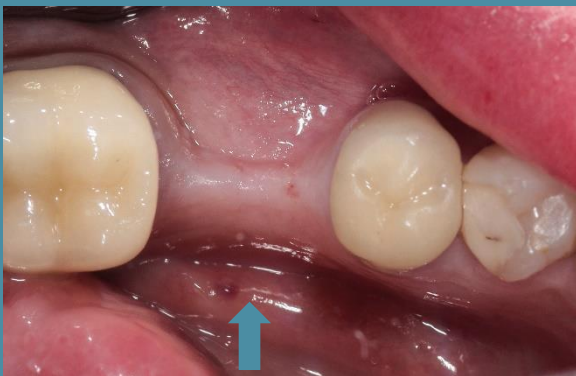Graft: Ivory's Dentin Bone Graft

Graft Cover: a collagen membrane, fixation pins, and two LPRF membranes on top

Application: Lateral augmentation and Implant placement, simultaneously

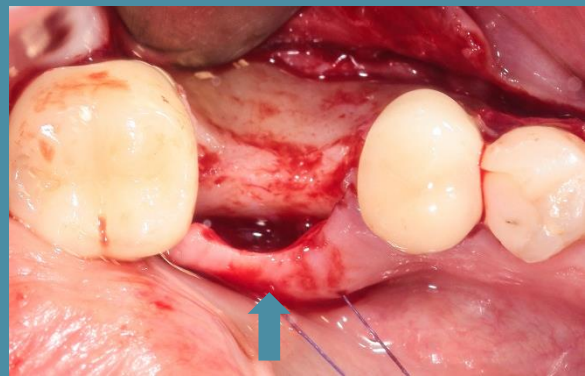
By: Dr. Avi Kuperschlag, D.D.S., Lithuania

Before Operation



Photograph

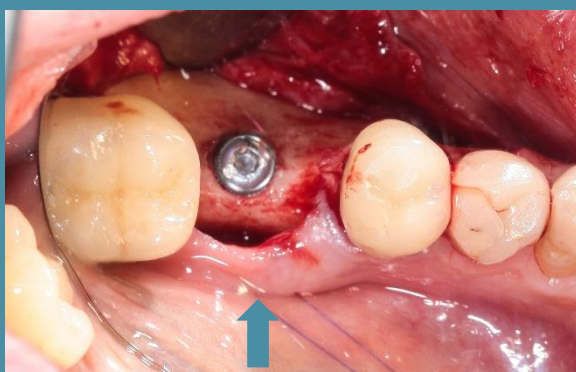
Before Implantation



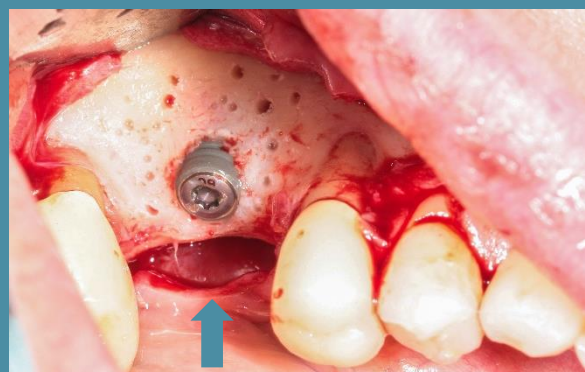Photograph

During Implantation

Photographs



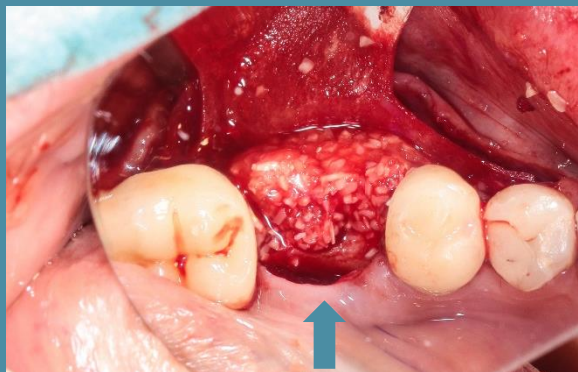
Implant placement



Implant placement

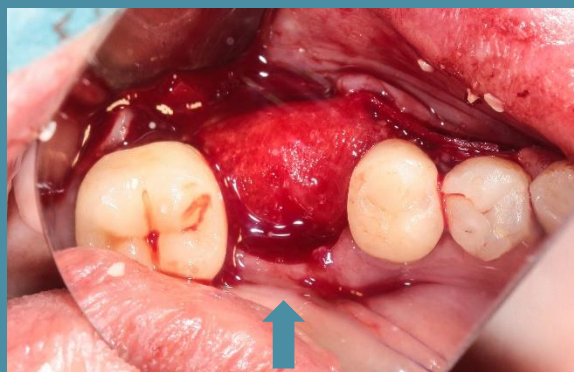
During Bone Grafting Photographs

1



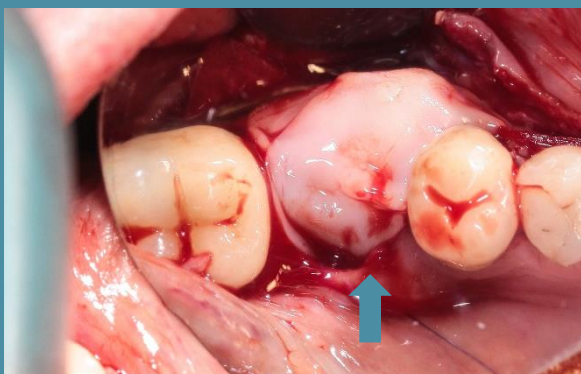
Bone graft added

2



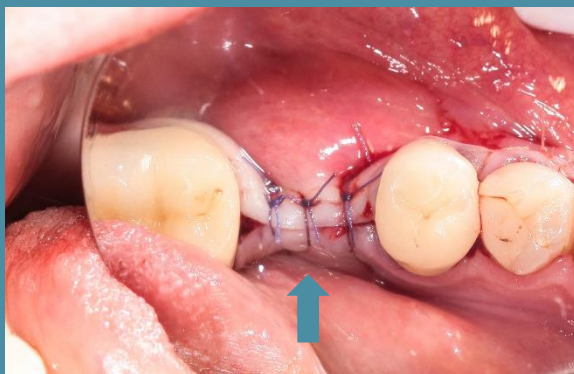
Collagen membrane added

3



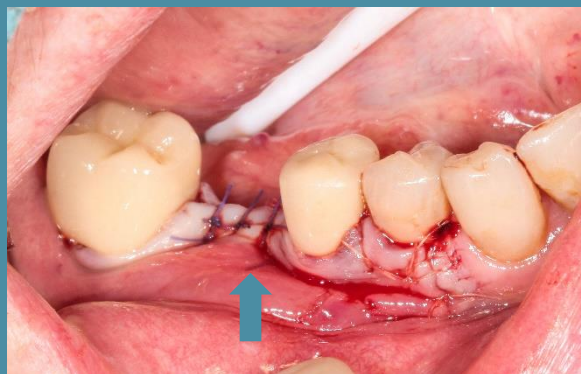LPRF membranes added

4



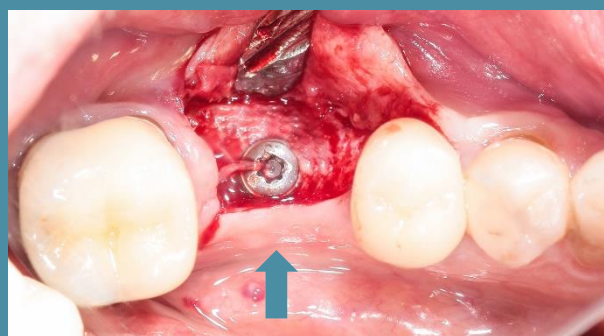
During Suturing

5



Suturing completed

4 Months After Bone Grafting



Photograph

“Great Looking regenerated bone.”

Dr. Avi Kuperschlag