

# IVORY Graft

## Case Report

**Patient:** Healthy Female, in here late 60's

**Medical condition:** Extraction of tooth 46, and implant placement for teeth 45,46

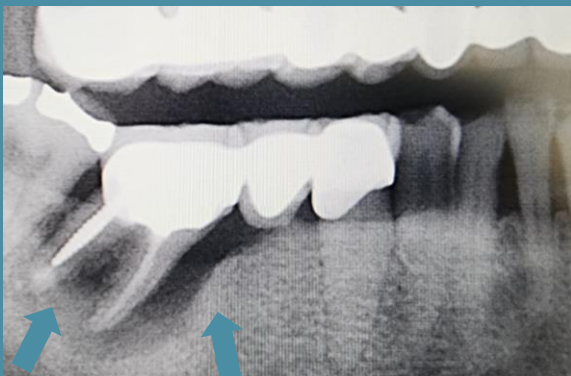**Graft:** Ivory's Dentin Bone Graft with APRF (Advanced Platelet Rich Fibrin)

**Graft Cover:** Bio-Gide collagen membrane

**Application:** Socket preservation

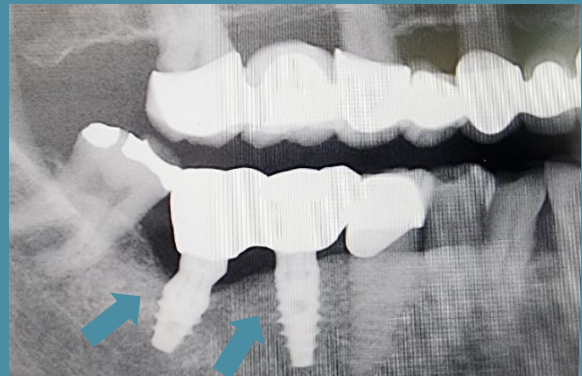
**By:** Dr. Jerry Kohen, DMD, Holon, Israel

Before Extraction

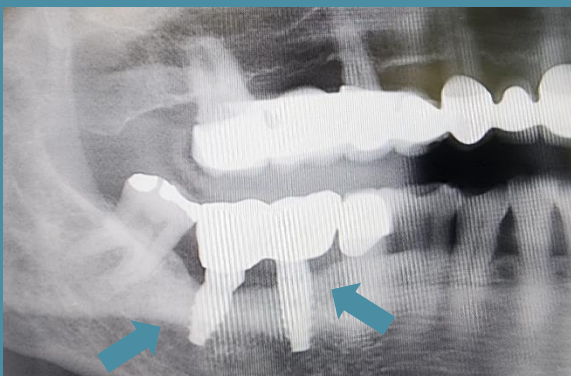

Panoramic scan

6 Months After Bone Grafting



1 Year After Bone Grafting



“Outstanding bone regeneration  
and implant stability  
with Ivory Dentin Graft”

Dr. Jerry Kohen